



National Guidelines for Self-breast Examination and Clinical Breast Examination



The screening protocol

- Breast self-examination should be conducted once a month by all women starting from 20 years of age.
- Clinical Breast Examination (CBE) is recommended every 3 years for all women from the age of 20 to 40 years. Women aged 40 or over, CBE is recommended annually.
- In women whose relatives had breast or ovarian cancer under the age of 40 years, annual clinical breast examination should be started 5 years before the index case.
- Breast self-examination should be taught and reinforced at every consultation.
- Screening mammography is offered once in 2-3 years for women aged 50 – 69 years. (Can be adopted only when adequate mammography facilities are available throughout the country)

Self-breast examination

Self-breast examination (SBE) is the inspection and palpation of the breast by the woman herself. The role of the primary health care physician/ staff is to provide necessary information to women and to make them competent in self-breast examination.

Information that should be provided to the woman:

Importance of SBE

If breast cancer is detected early, it gives a better outcome. A practice of self-breast examination on a monthly basis is very important for early detection of breast cancers.

Best time to conduct the SBE

It is better to conduct SBE one week after the beginning of menstruation (During menstruation, some women feel their breasts painful and lumpy). If she is not menstruating, a convenient fixed date should be selected.

Frequency of carrying out the SBE

This should be carried out once a month by all women over the age of 20 years.

Required setting to carry out the SBE

This procedure takes little time and can be incorporated into the routine life activity, in any place that is comfortable and would secure the privacy of the woman.

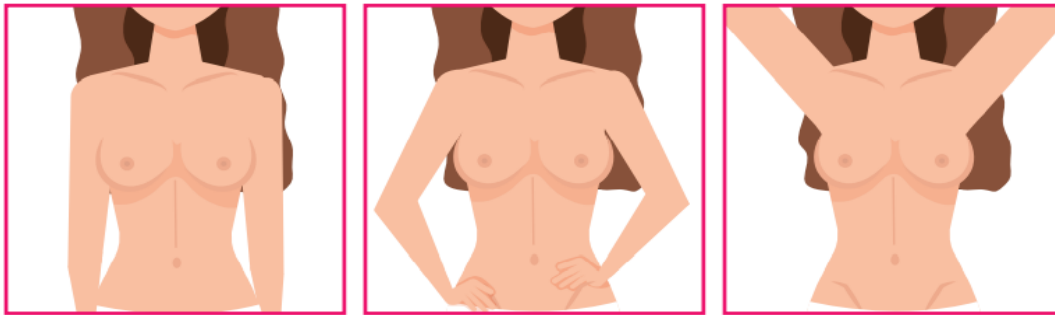
Steps of self-breast examination:

Two components:

1. Inspection (Preferably in standing position)
2. Palpation (Either lying down, sitting, standing)

Inspection

Stand in front of the mirror exposing the chest up to the waist, look at the breasts through the mirror, while keeping the arms in positions.



1. Arms hanging by the side
2. Hands pressed on the hips
3. Arms raised over the head

Figure I: Positions of Breast inspection

Note the changes mentioned below:

- Skin changes of the breasts
- Color changes of the breasts
- Change in shape of the breasts
- Orange peel / Peau d'orange appearance of the breast
- Ulceration on the breast
- Late occurrence of breast asymmetry (most women may have asymmetry in normal circumstances. Therefore, a long-standing breast asymmetry is not a sign of a cancer)
- Nipple changes, discharges other than breast milk/ inverted nipple (having inverted nipples from birth is not a sign of a cancer)
- Breast lump, change in the texture, thickening of the breast skin.
- Lumps in the arm pit or around the neck

Palpation of the breasts while standing

Palpate the breast using middle three fingers to identify thickened areas and or lumps. Use the palmar surfaces of the fingers (flat surface of the three middle fingers). Palpation of breast can be done in sitting or lying down positions.

On examining right breast, raise the right arm over the head and palpate the right breast using the left hand. While examining the left breast raise the left arm and palpate the left breast using the right hand.

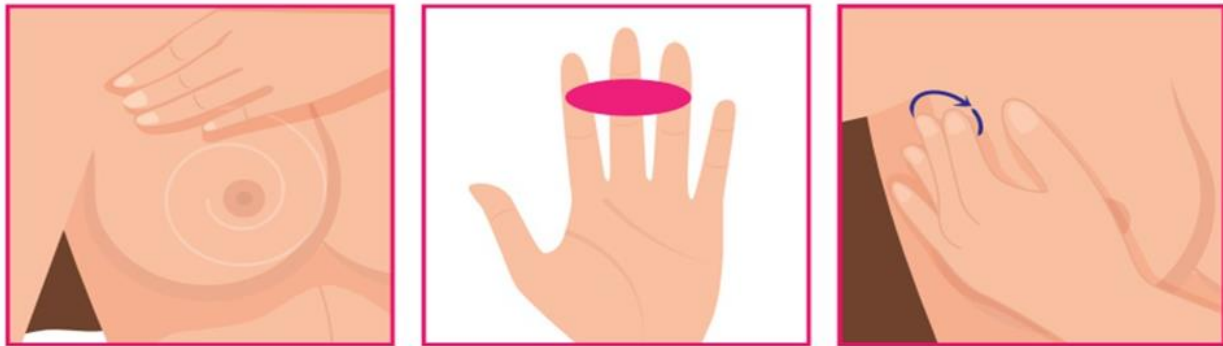

Figure II: Palpation of the breast

Continue palpating the breast in a clockwise direction from outer circle of the breast towards the nipple using three pressure levels.

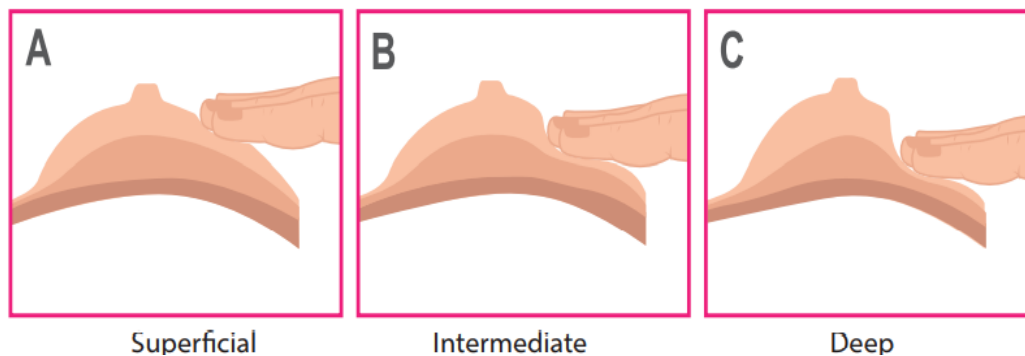


Figure III: Palpation of the breasts in superficial, intermediate and deep pressure levels

Start with applying 'minimal' pressure as indicated (to feel the area just beneath the skin) and then gradually increase the pressure (to feel the tissue deeper within).

At the end of the breast palpation, find out whether there is a nipple discharge by squeezing the areola using thumb and middle finger.

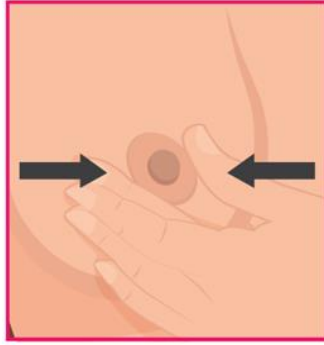


Figure IV: Look for nipple discharge.

Then examine the armpit and look for lumps. Use the same technique to examine the other breast.

Palpation of breast in lying down position.

To palpate the right breast, keep the right palm beneath the head and palpate the breast using the left hand. For the palpation of left breast, keep the left palm under the head and palpate with the right hand.

If any abnormality is detected during self-breast examination, it is necessary to consult a doctor even though all the changes may not be due to breast cancer.

Clinical breast examination

Clinical breast examination serves two purposes. It can be used as a screening method for women without any signs and symptoms of breast cancer and as a component of triple assessment in women with signs and symptoms when diagnosing breast cancer. A detailed history and thorough clinical examination provide important information on which, further investigations would be based.

Clinical history

History should be taken from women presenting to the clinic, either with signs and symptoms or without signs and symptoms before doing clinical breast examination. Following are the possible signs and symptoms and information need to be collected.

Possible signs and symptoms and information to be collected:

<p>Breast Lump</p>	<ul style="list-style-type: none"> • Site - Constant and changing • Duration- when and how it was noticed. • Any new changes since first notice (e.g., getting bigger) • Relationship to menstrual cycles or exogenous hormones • Associated symptoms
<p>Breast Pain</p>	<ul style="list-style-type: none"> • Site- Constant or changing/ unilateral or bilateral. • Cyclical or noncyclical • Duration - how long and characteristics of pain • Any recent change such as intensity, frequency, site of pain • Relationship to menstrual cycles or exogenous hormones • Associated symptoms
<p>Nipple discharge or any other nipple changes</p>	<ul style="list-style-type: none"> • Duration - when and how first noted (Spontaneous or not) • Any changes since first notice • Bilateral or unilateral • From single duct or multi duct

Following information also need to be gathered in addition to signs and symptoms.

- Previous history of pathological condition (either breast)
- Previous breast investigations:
 - Most recent imaging if available (Screening or diagnostic) date and results
 - Biopsy results - FNAC/Histology/Lumpectomy
- Risk factors - Try to identify risk factors.

Steps of Clinical Breast Examination (CBE)

CBE should be done in a covered room with good light. A female chaperon should be there if the examiner is a male. Before starting the examination, it is necessary to explain the procedure to the client.

Inspection

Breasts should be inspected in each of the following positions:

1. Arms relaxed at her sides
2. Hands placed on the hips and pushing inward (contraction of the Pectoralis Major muscle)
3. Arms raised over her head

The breasts should be inspected from the front and from each side. Pay particular attention to:

- Breast size, contour, shape, symmetry
- Skin changes such as erythema, dimpling, tethering or puckering, Peau d' orange, eczematous skin changes, visible lumps.
- Nipple – position, inversion, retraction, erythema, eczema, nodules

Palpation

The ability to identify breast lumps by palpation is influenced by the characteristics of the tumour, the surrounding breast tissue, the position of the lesion in the breast, proper positioning of the client and thoroughness of the search, the area covered and use of a consistent pattern of search. During the process of palpation, the client should feel comfortable and need to ask about it.

• Positioning the woman for palpation

For the palpation of the breasts, the woman should be placed in the supine position, placing both arms under her head, which will facilitate palpation of the outer quadrant of a large breast. Use the examiner's other hand to stabilize breast in position.

Perimeter of the breast should be noted during clinical breast examination.

Anatomically, breast tissue extends superiorly from the second rib or clavicle, medially to the lateral border of the sternum, inferiorly to the sixth rib and laterally to the Latissimus Dorsi muscle.

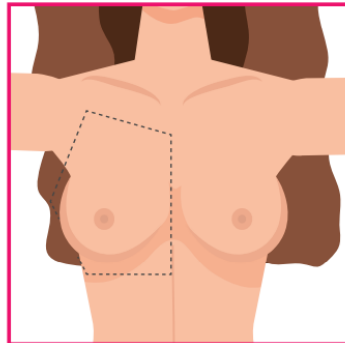


Figure V: Perimeter of the breast

Palpation technique

The examiner should use the distal phalanges of the middle three fingers to palpate the breast. The entire breast should be palpated using overlapping dime-sized circles. Use three different levels of pressure (superficial, intermediate and deep) at each point to palpate different layers of the breast.

(See Figure III)

There are three typical patterns used to palpate the breast:

- Circular technique
- Radial spoke technique (wedges)
- Vertical strip technique (lines)

Whichever pattern is used for palpation of the breasts, it is important to make sure that the entire perimeter of the breasts are being covered.

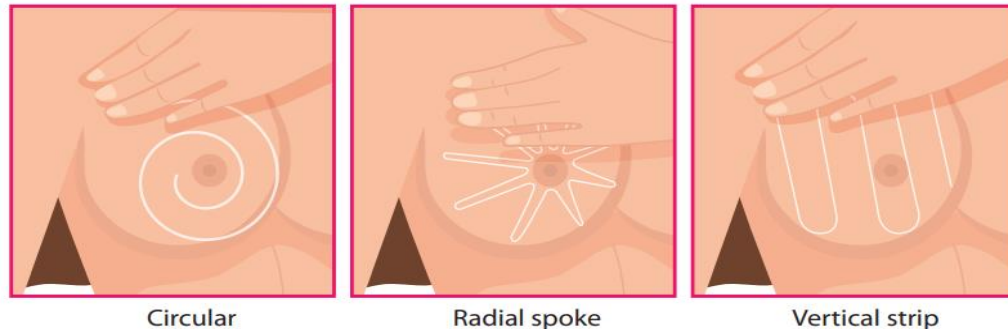


Figure VI: Three patterns of breast palpation

The woman should be asked to squeeze areolar region of the nipple to see whether there is any nipple discharge. (Nipple discharge that occurs only with nipple or breast stimulation is a normal physiological function.)

(See Figure IV)

Palpation of Regional Lymph Nodes

The regional lymph nodes (Supra-clavicular, Infra-clavicular and axillary nodes) should be palpated while woman is in the sitting position.